# An Increase of Sigma-1 Receptor in the Penumbra Neuron after Acute Ischemic Stroke

Xiaotian Zhang, MS,* Fangfang Wu, MS,*,† Yun Jiao, PhD,‡ Tianyu Tang, PhD,‡ Li Yang, BS,* Chunqiang Lu, MS,‡ Yanhong Zhang, BS,* Yuan Zhang, PhD,* Ying Bai, MS,* Jie Chao, PhD,§ Gaojun Teng, PhD,‡ and Honghong Yao, PhD*,‖

*Background:* Penumbra salvage from infarction by early reperfusion within the time window is the target of acute ischemic stroke therapies. Although the penumbral imaging is potently usable in clinic trial, additional work needs to be performed to advancing the field with better-defined, evaluated, and validated imaging measures. *Methods:* Mice were subjected to permanent stroke by right middle cerebral artery (MCA) occlusion. Multimodel magnetic resonance imaging (MRI) method was assessed to define the penumbra as that brain region in which the perfusion and diffusion-weighted MR images are mismatched (perfusion-weighted imaging [PWI]-diffusion-weighted imaging [DWI] mismatch). MRI measurements were performed at 1 hour after MCA occlusion (MCAO). Sigma-1 receptor expression was assessed by immunoblotting and immunostaining in PWI-DWI–defined penumbra and core compared with sham or contralateral slice. Penumbral sigma-1 receptor identified the correlation with the neuron, astrocyte, and microglia by immuno-colocalization. *Results:* Sigma-1 receptor was significantly upregulated in penumbra or peri-infarct compared with sham and core tissue at 1 hour and 24 hours after MCAO. There was a colocalization of sigma-1 receptor and neuron in penumbra at 1 hour after stroke. Sigma-1 receptor is specifically increased in ischemic penumbral neuron at 1 hour after MCAO. *Conclusions:* Sigma-1 receptor may act as an endogenous marker of penumbra after acute ischemic stroke.

From the *Department of Pharmacology; †Department of Neurology, Zhongda Hospital, Neuropsychiatric Institute, School of Medicine, Southeast University, Nanjing, Jiangsu, China; ‡Jiangsu Key Laboratory of Molecular and Functional Imaging, Department of Radiology, Zhongda Hospital, Medical School of Southeast University, Nanjing, Jiangsu, China; §Department of Physiology, School of Medicine; and ‖Institute of Life Sciences, Key Laboratory of Developmental Genes and Human Disease, Southeast University, Nanjing, Jiangsu, China.

Received March 9, 2017; revision received May 21, 2017; accepted June 4, 2017.

Grant support: This work was supported by grants from the National Natural Science Foundation of China (No. 81322048, No. 81473190, No. 81673410, and No. 81603090), as well as grants from the Jiangsu Specially Appointed Professor and the Major State Basic Research Development Program of China (973 Program) (2013CB733800 and 2013CB733803) and the Postdoctoral Research Start Foundation of Southeast University (1124000342).

Author Contributions: H.Y. planned and designed the research, and contributed to final approval of the version to be submitted; X.Z. performed the MCAO surgery, immunofluorescence and Western blot assays; F.W. performed the immunohistochemistry, data processing, and drafted the article; Y.J. performed MRI scan; T.T. performed MRI data analysis; L.Y. performed gadolinium injection; C.L. contributed to the MRI data collection; Y.Z. contributed to the image analysis; Y.Z. performed tissue separation; Y.B. performed animal sacrifice; J.C. contributed to the project discussion; G.T. discussed the project and gave valuable suggestions to this project.

Xiaotian Zhang and Fangfang Wu contributed equally to this work.

Address correspondence to Honghong Yao, PhD, Department of Pharmacology, School of Medicine, Southeast University, No.87 Dingjiaqiao Road, Gulou District, Nanjing, Jiangsu, China. E-mail: yaohh@seu.edu.cn.

1052-3057/$ - see front matter



http://dx.doi.org/10.1016/j.jstrokecerebrovasdis.2017.06.013

**Key Words:** Sigma-1 receptor—perfusion-weighted imaging—diffusion-weighted imaging—magnetic resonance imaging—mice—ischemic stroke.


## Introduction

Ischemic stroke is a common neurological disorder worldwide and is one of the major causes of permanent disability.[1] Clinical treatments, such as tissue plasminogen activator thrombolysis, are often limited by the acute narrow time window,[2] and long-term therapeutics remain limited.[3] The ischemic penumbra was defined as "a zone of nonfunctioning but still viable tissue that may recover its function if blood flow can be restored, for example, by therapeutic intervention."[4] This concept revealed 2 cerebral blood flow (CBF) thresholds of ischemia: a lower threshold, which represented function and structural impairment that was associated with ischemic core; and an upper threshold, which defined electrical failure, representing functionally failed but structurally intact tissue.[5] The ischemic penumbra represented tissue between these 2 thresholds. If a successful interruption does not occur, the ischemic core will expand and the penumbral tissue will be inverted into infarcted volume. Penumbral salvage from infarction by early reperfusion within the time window is the target of acute ischemic stroke therapies. The penumbral zone can be estimated in magnetic resonance imaging (MRI). Multimodal MRI diffusion-weighted imaging (DWI) has demonstrated to delineate irreversibly injured region, and perfusion-weighted imaging (PWI) provides the assessment of delineating the extent of reversible tissue. The penumbral zone can be verified by the mismatch of diffusion- and perfusion-weighted sequences.[6] Several clinical studies have demonstrated the potential applications of diffusion-perfusion mismatch to imaging salvageable penumbral tissue as a surrogate end point for reperfusion therapies in acute stroke.

Sigma receptors are wildly expressed in mammalian brain, and these receptors are classified into 2 members, namely sigma-1 receptor and sigma-2 receptor. Several studies suggest that sigma-1 receptors are implicated in numerous physiology and pathophysiology of central and peripheral diseases, such as ischemic stroke,[7] Alzheimer's disease,[8] Parkinson's disease,[9] pain,[10] NeuroAIDS,[11] and psychiatric disorders.[12] Sigma-1 receptor is a novel molecular chaperone regulating $Ca^{2+}$ efflux from the neural endoplasmic reticulum to the mitochondria.[13] Recent findings reveal that upon the agonists, sigma-1 receptor can translocate to plasma membrane and interact with receptors, protein kinases, and ion channels,[14] regulating neurotransmitter release, protein kinases location or activation, cell redox, neural survival, and inflammation.[15]

A previous study has shown that sigma-1 receptor activation stimulates recovery after stroke by enhancing intracellular trafficking of biomolecules required for brain repair, thereby enhancing synaptogenesis and brain plasticity.[7] Although no significant effects on functional end points were seen in the population as a whole, [1-(3,4-dimethoxyphenethyl)-4-(3-phenylpropyl)-piperazinedihydrochloride, (SA4503)], a selective sigma-1R agonist saw a greater improvement in patients with greater pretreatment deficits in post hoc analysis in the phase II clinic trail in patients with ischemic stroke.[16] It prompted a potential application in patients with moderate-to-severe stroke.

In our present study, specific upregulation of sigma-1 receptor was found in peri-infarct tissue of mouse ischemic brain. Based on the observation that activation of sigma receptors provides potent neuroprotection in ischemic stroke[7,17,18] and the penumbra was defined as a brain area that was damaged but not yet dead after stroke, we thought that there may be a possible relevance between sigma-1 receptor and penumbra. To determine the relationship between the 2 variables, we used multimodel MRI method to define a penumbra as PWI-DWI mismatch, and in combination with the immunostaining, the expression of sigma-1 receptor in the penumbral area was observed. By comparing PWI-DWI mismatch and tissue staining, our data suggest that sigma-1 receptor increases in ischemic penumbral neuron. We, therefore, hypothesize that sigma-1 receptor could act as an endogenous marker of the penumbra after acute ischemic stroke.

## Methods

### *Animals*

Male C57BL/6J mice weighing 22~25 g were purchased from the Model Animal Research Center of Nanjing University (Nanjing, China). Mice were maintained on a 12-hour light-dark cycle at 25°C and provided with free access to commercial rodent chow and tap water before the experiments. Animals were simple randomly assigned to sham and stroke groups. One animal was excluded from the study because of nonobvious ischemic lesion sizes in $T_2$ maps at 1 hour after stroke. MRI data were collected by operators blinded to the project. All the animal surgical procedures were approved by the University Committee on Animal Care of Southeast University and in strict compliance with the guidelines of the Council Directive of EC (86/609/EEC).

### *Photothrombotic Middle Cerebral Artery Occlusion*

Mice were anesthetized intraperitoneally with sodium phenobarbital (100 mg/kg), and rectal temperature was maintained at 37°C ± 1.0°C with a heating pad throughout the surgical procedure. Stroke was generated by making

an incision between the right orbit and the right external auditory canal under a stereoscopic microscope. Briefly, as reported earlier,[19] the scalp and temporalis muscle were exposed and the zygomatic arch was snipped to expose the proximal section of the right middle cerebral artery (MCA). To effectively occlude the right MCA, immediately after intravenous injection of a photosensitizer rose bengal solution (100 mg/kg, 10 mg/mL in normal saline; Sigma-Aldrich) through the tail vein, photoillumination with green laser (wavelength 532 nm, GL532TA-100FC, Shanghai Laser & Optics Century, Shanghai, China) was performed on the MCA for 2 minutes by using a 100-µm optic fiber connected to a laser diode controller (power at 35, ADR-1805, Shanghai Laser & Optics Century). Mice were then allowed to awaken and were returned to their cages. Total surgery lasted for up to 20 minutes. There was no surgery-related mortality noted. Sham operation was performed with the same surgical procedures but with injection of .01 mol/L phosphate-buffer saline (PBS) instead.

### *MRI*

Eight mice were imaged separately at 1 hour after permanent MCA occlusion (pMCAO). Animals were anesthetized with isoflurane-air (3% for induction-1% for maintenance) for all MRI scans. MRI was carried out on a 7.0 Tesla small animal magnetic resonance system (Bruker PharmaScan, Ettlingen, Germany). The method for mice MRI measurements is modified as described.[20,21] Briefly, 2-dimensional $T_2$-weighted, perfusion-, and diffusion-weighted images were executed in an axial plane. Slice thickness and matrix size are modified as follows: field of view: 20 mm; $64 \times 64$ matrix; slice thicknesses: 1 mm (DWI and $T_2$WI) and 2 mm (PWI). Areas related to abnormal apparent diffusion coefficient and $T_2$ in the ipsilateral hemisphere were determined using the threshold of mean −1 s.d. and mean +2 s.d. of contralateral nonischemic hemisphere. Areas related to abnormal CBF in the ipsilateral hemisphere were determined by measuring the number of pixels with CBF below 50 mL/100 g $\times$ min$^{-1}$. For perfusion scans, a gadolinium (.1 mmol/kg) bolus was injected intravenously, starting on the third repetition with a total injection time of 7 seconds through a peripheral intravenous port. We were able to detect the ischemia core and penumbra using PWI-DWI mismatch.

### *Western Blot Analysis*

The penumbra and the infarct core were removed after 1 hour, 3 hours, 8 hours, 24 hours, 3 days, and 14 days of the pMCAO. The proteins were extracted in RIPA lysis buffer (Beyotime, P0013B, Shanghai, China). The proteins were separated by sodium dodecyl sulfate-polyacrylamide gel electrophoresis (12%) and electrophoretically transferred onto polyvinylidene fluoride membranes. The membranes were blocked with 5% nonfat dry milk in Tris-buffered saline with Tween-20, probed with antibodies overnight at 4°C, and then incubated with horseradish peroxidase-conjugated goat anti-mouse-rabbit immunoglobulin G (IgG) secondary antibody (1:2000). The antibodies used were as follows: anti-SIGMAR1 (15168-1-AP) from Proteintech (Wuhan, China) and anti-β-actin (AB39199) from AbSci (College Park, MD, USA). Detection was performed using a MicroChemi4.2 (DNR, Neve Yamin, Israel) digital image scanner. Band intensity was quantified by ImageJ software (National Institutes of Health, Bethesda, MD).

### *Immunohistochemistry*

After MRI, animals were perfused with .01 mol/L PBS, followed by 4% paraformaldehyde. Brains were removed and post-fixed overnight in the same solution. The sections encompassing the entire corpus striatum were cut into 30-µm sections on a cryostat. The sections were permeabilized with .3% Triton X-100 in .01 mol/L PBS for 30 minutes and blocked with 10% normal goat serum in .3% Triton X-100 for 1 hour at room temperature. The sections were then incubated with anti-SIGMAR1 (15168-1-AP) from Proteintech overnight at 4°C. The next day, the sections were washed, incubated with biotinylated goat anti-rabbit IgG (Vector Laboratories, BA-1000, Burlingame, CA, USA) in PBS for 1 hour at room temperature, and then incubated with VECTASTAIN (VECTASTAIN ABC Kit, Vector Laboratories, PK-6200) for 1 hour. The horseradish peroxidase reaction product was visualized using an enhanced 3,3′-diaminobenzidine peroxidase substrate kit (Vector Laboratories, SK-4100).

### *Immunofluorescence Staining*

Double immunofluorescence was performed to evaluate colocalization of sigma-1R with neuronal nuclei (NeuN) for neuron, glial fibrillary acidic protein (GFAP) for astrocyte, and ionized calcium binding adaptor molecule 1 (Iba-1) for microglia. The sections were permeabilized with .3% Triton X-100 in PBS for 30 minutes and blocked with 10% normal goat serum in .3% Triton X-100 for 1 hour at room temperature. After that, the sections were incubated with mouse anti-SIGMAR1 antibodies (1:50, sc-137075, Santa Cruz Biotechnology, Santa Cruz, CA, USA) and rabbit anti-NeuN (1:200, 23060-1-AP, Proteintech) or rabbit anti-GFAP (1:200, 16825-1-AP, Proteintech) or rabbit anti-Iba1 (1:200, 019-19741, Wako, Osaka, Japan) overnight at 4°C. The sections were washed and incubated with Alexa Fluor 488-conjugated anti-mouse and Alexa Fluor 594-conjugated anti-rabbit IgG (Invitrogen, Grand Island, NY).

### *Statistical Analysis*

Statistical analysis was performed using GraphPad Prism 5.01. Data were presented as the mean ± standard error of the mean. Results from different time points of sigma-1 receptor were analyzed using 1-way analysis of variance. For comparison between 2 groups, the Student's *t*-test and

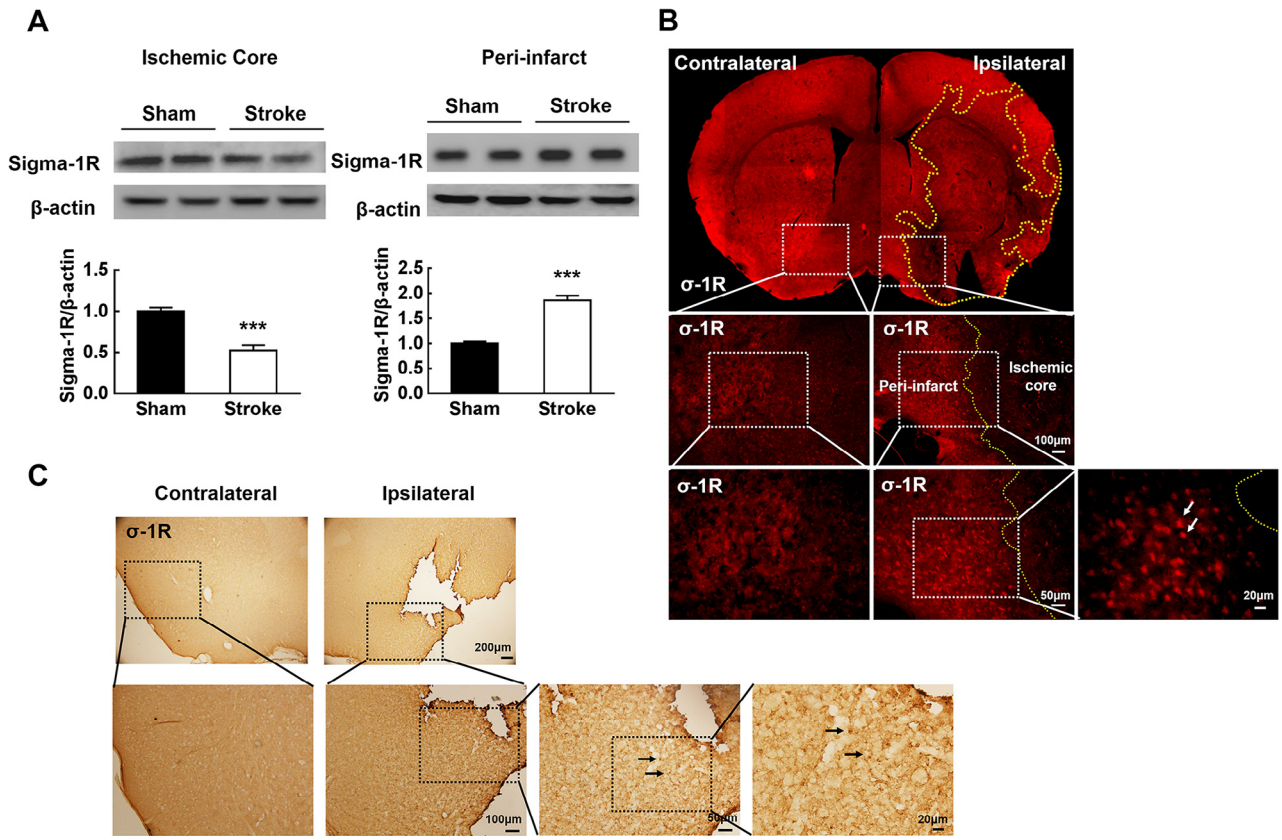


**Figure 1.** *The expression of sigma-1 receptor increased in the peri-infarct than in the ischemic core at 24 hours after pMCAO. (A) Representative Western blot showed that in the peri-infarct, the expression of sigma-1R increased compared with the sham group, whereas in the ischemic core, the expression was decreased (n = 4; ***P < .001 versus the sham group using Student's* t*-test). (B) Representative immunofluorescence staining of sigma-1R (red, arrows) in the ipsilateral brain slice and contralateral brain slice at 24 hours after pMCAO. Yellow dashed line denotes the ischemic area (10×, scar bar: 100 μm; 20×, scar bar: 50 μm; 40×, scar bar: 20 μm). (C) The increased expression of sigma-1R (arrows) in the peri-infarct was followed immunohistochemistry staining. (4×, scar bar: 200 μm; 10×, scar bar: 100 μm; 20×, scar bar: 50 μm; 40×, scar bar: 20 μm). Abbreviation: pMCAO, permanent middle cerebral artery occlusion. (Color version of figure is available online.)*

the Tukey's multiple comparison test were used. *P* values less than .05 were considered as statistically significant.

## Results

### *Sigma-1 Receptor Is Increased in Peri-Infarct Tissue after Acute Ischemic Stroke*

To evaluate the expression of sigma-1 receptor after acute stroke, we tested the protein expression between pMCAO and sham operation in ischemic core and peri-infarct tissue. Sigma-1 receptor as assessed by Western blot (Fig 1, A) was significantly increased in peri-infarct at 24 hours after ischemic lesion compared with sham mice ($P < .001$), and was decreased in ischemic core ($P < .001$). This finding was further confirmed by immunostaining (Fig 1, B,C), sigma-1 receptor was increased in peri-infarct tissue compared with contralateral tissue at 24 hours after ischemic stroke.

**Figure 2.** *The expression of sigma-1 receptor increased in the penumbra compared with the ischemic core at 1 hour after pMCAO. (A) The $T_2$, ADC, and CBF information of the mice at 1 hour after pMCAO from MRI. The red area represents region of interest in DWI. White dashed line denotes the region of interest in PWI imaging. Gray area represents PWI-DWI mismatch area. (B) Representative immunofluorescence staining of sigma-1R (green) in the ipsilateral brain slice and contralateral brain slice at 1 hour after pMCAO. Yellow dashed line denotes the ischemic area (10×, scar bar: 100 μm). (C) The expression of sigma-1R at 1 hour after pMCAO in the sham group, penumbra, and ischemic core (n = 4; **P < .01, ***P < .001 versus the sham group, ###P < .001 versus ischemic core using 1-way ANOVA followed by the Tukey's multiple comparison test). (D) Identification of sigma-1R-expressing cells in the ischemic penumbra. Representative immunofluorescence staining of sigma-1R (green), NeuN (red), GFAP (red), and Iba-1 (red) in the ipsilateral brain slice at 1 hour after pMCAO. Z-stack reconstruction was used for analysis of sigma-1 receptor and NeuN, GFAP, or Iba-1 colocalization in penumbra. Arrows indicated the colocalization of sigma-1 receptor with NeuN (20×, scar bar: 50 μm; 63×, scar bar: 10 μm). Abbreviations: ADC, apparent diffusion coefficient; ANOVA, analysis of variance; CBF, cerebral blood flow; DWI, diffusion-weighted imaging; GFAP, glial fibrillary acidic protein; Iba-1, ionized calcium binding adaptor molecule 1; MRI, magnetic resonance imaging; NeuN, neuronal nuclei; pMCAO, permanent middle cerebral artery occlusion; PWI, perfusion-weighted imaging. (Color version of figure is available online.)*

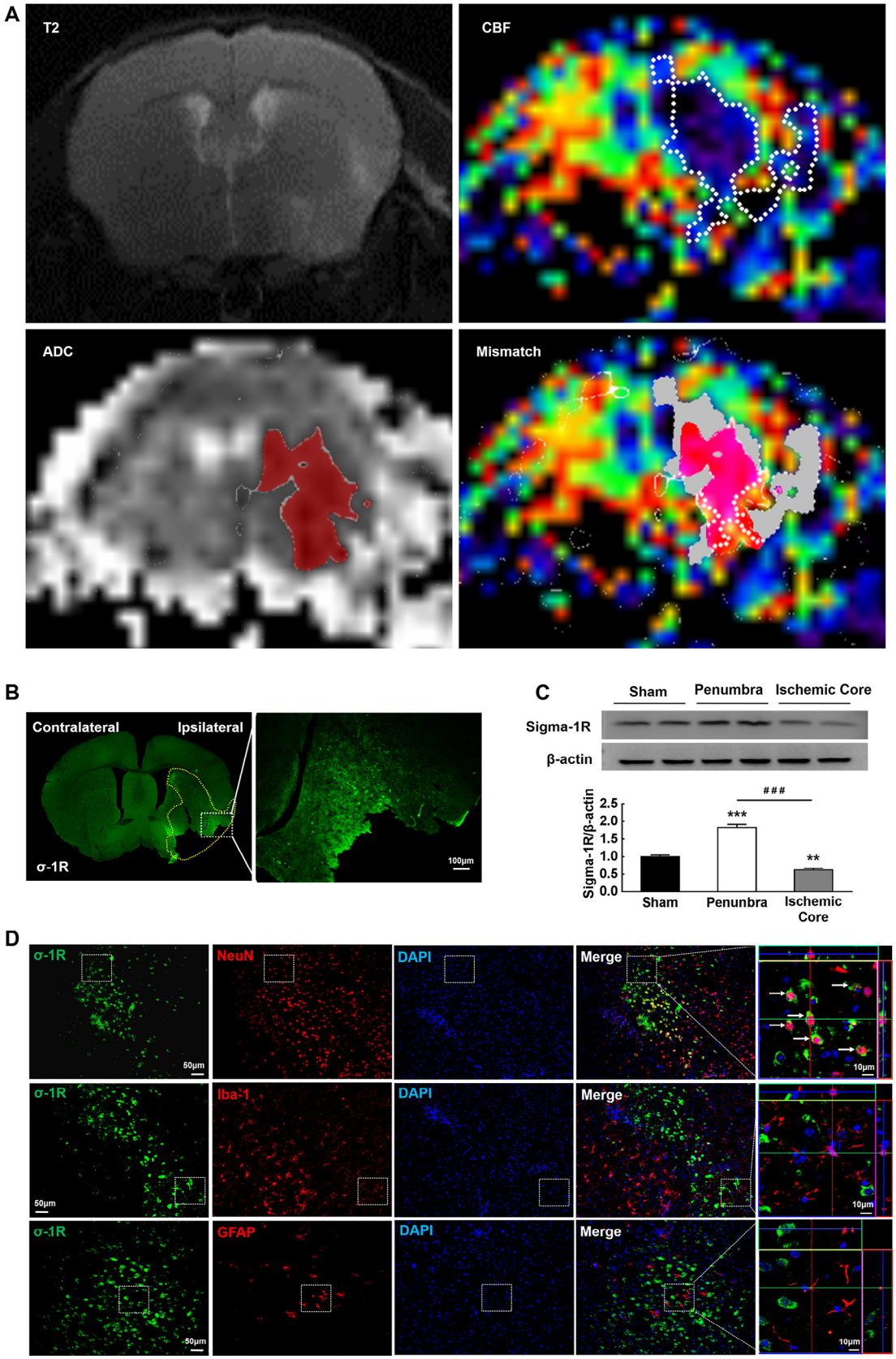
A
T2
CBF
ADC
Mismatch
B
Contralateral
Ipsilateral
σ-1R
100μm
C
Sham
Penumbra
Ischemic Core
Sigma-1R
β-actin
Sigma-1R/β-actin
2.5
2.0
1.5
1.0
0.5
0.0
***
**
###
Sham
Penunbra
Ischemic Core
D
σ-1R
NeuN
DAPI
Merge
50μm
10μm
Iba-1
GFAP

*Sigma-1 Receptor Was Increased in Penumbra Other Than Ischemic Core at 1 Hour after Ischemic Stroke*

Having determined that the expression of sigma-1 receptor was significantly increased in peri-infarct tissue compared with contralateral tissue, we next sought to determine whether the increased sigma-1 receptor was restricted in the penumbra of the ipsilateral side of the brain with pMCAO. Therefore, we resorted to MRI analysis to match the peri-infarct tissue with the penumbra of the ipsilateral side of the brain. One hour after pMCAO, a significant increase in brain edema was showed in the $T_2$-weighted scan (Fig 2, A). PWI-DWI mismatch was used to define the penumbral area in stroke mice (Fig 2, A). After MRI analysis, the mouse was sacrificed, and the expression of sigma-1 receptor at 1 hour after pMCAO in the penumbra was determined using immunostaining (Fig 2, B). As shown in Figure 2, C, the expression of sigma-1 receptor at 1 hour after pMCAO in the penumbra was significantly increased compared with the sham group ($F_{2,9} = 87.09$, $P < .001$) and the ischemic core ($P < .001$) (Fig 2, C), whereas the expression of sigma-1 receptor was decreased in ischemic core compared with the sham group ($P < .01$) (Fig 2, C). Next, to determine the cell type of sigma-1 receptor expression, we detected 3 markers of neuron (NeuN), astrocyte (GFAP), and microglia (Iba-1). As shown in Figure 2, D, there is colocalization of sigma-1 receptor with NeuN but not GFAP or Iba-1 in the penumbral area at 1 hour after stroke.

## Discussion

Over the past years, multimodel imaging has offered much promise for stroke investigators and clinicians, especially those interested in using imaging to optimize and extend the time window for acute ischemic stroke therapies. However, applications that use neuroimaging as a surrogate end point to test interventions has yet to be fully realized. Although several studies have proposed a number of approaches to identify salvageable penumbral tissue, the most widely embraced to date has been diffusion-perfusion mismatch.[22] However, the human penumbral imaging for acute stroke therapies selection is not as simple as diffusion-perfusion mismatch.

The peri-infarct tissue is thought to be the major target of neuroprotective therapies in pharmacological approaches. We found that sigma-1 receptor was significantly increased in peri-infarct tissue at 24 hours after stroke. Then, we also detected the expression of sigma-1 receptor at different time points within 14 days. We found that sigma-1 receptor was significantly increased in peri-infarct at 1 hour, 3 hours, 8 hours, 24 hours, and 3 days after ischemic lesion compared with sham mice; however, there is no significant difference for the level of sigma-1 receptor expression in peri-infarct at 14 days compared with that in the sham group (Supplementary Fig S1). The clinical time window of perfusion therapy is always within several hours after ischemia. With the definition of PWI-DWI mismatch as penumbra in mouse brain, we compared the difference of sigma-1 receptor expression between ischemic penumbra and core at 1 hour after stroke. The localization of penumbra and core was based on the MRI features. Our results indicated that sigma-1 receptor was significantly upregulated in penumbra compared with sham and core tissue. In our study, sigma-1 receptor was decreased in ischemic core compared with sham. We also found that sigma-1 receptor was highly expressed in the penumbral neuron at 1 hour after stroke. Previous studies reported that sigma-1 receptor levels were higher in ipsilateral tissue than in the contralateral side at 2 weeks after permanent MCAO in both striatal and cortical tissues. Sigma-1 receptor and GFAP immunoreactivities indicated colocalization in astrocyte in the brain of rats subjected to transient MCAO and 1 week recovery.[7] The difference between our data and previous studies might be owing to the different time phases of ischemic stroke. In the acute stroke within hours, neurons were more vulnerable by ischemic stress than glial cells. Sigma-1 receptor, as an endoplasmic reticulum protein, could be activated immediately to protect neurons against ischemia and hypoxia.

In the past decades, many radionuclide-labeled ligands of sigma-1 receptor have been reported.[23,24] Several radiotracers have been evaluated in humans, although further investigation is still required for their clinical translation. Combined use of sigma-1 receptor imaging with micro positron emission tomography and multimodel MRI in penumbral imaging might be operated in further studies. Sigma-1 receptor represents a potential target for both diagnosis and therapeutic development of ischemic stroke.

In summary, our results suggested that the expression of sigma-1 receptor is specifically increased in ischemic penumbral neurons within hours. Sigma-1 receptor may be a new endogenous biomarker of penumbra after acute ischemic stroke. The present study adds to the credence of literature defining salvageable penumbra as a therapeutic target in ischemic stroke.

## Appendix: Supplementary Material

Supplementary data to this article can be found online at doi:10.1016/j.jstrokecerebrovasdis.2017.06.013.

## References

1. Lozano R, Naghavi M, Foreman K, et al. Global and regional mortality from 235 causes of death for 20 age groups in 1990 and 2010: a systematic analysis for the Global Burden of Disease Study 2010. Lancet 2012;380:2095-2128.
2. Goldstein LB. Acute ischemic stroke treatment in 2007. Circulation 2007;116:1504-1514.
3. George PM, Steinberg GK. Novel stroke therapeutics: unraveling stroke pathophysiology and its impact on clinical treatments. Neuron 2015;87:297-309.

4. Astrup J. Energy-requiring cell functions in the ischemic brain. Their critical supply and possible inhibition in protective therapy. J Neurosurg 1982;56:482-497.
5. Ford AL, An H, Vo KD, et al. Defining the ischemic penumbra using hyperacute neuroimaging: deriving quantitative ischemic thresholds. Transl Stroke Res 2012;3:198-204.
6. Neumann-Haefelin T, Wittsack HJ, Wenserski F, et al. Diffusion- and perfusion-weighted MRI. The DWI/PWI mismatch region in acute stroke. Stroke 1999;30:1591-1597.
7. Ruscher K, Shamloo M, Rickhag M, et al. The Sigma-1 receptor enhances brain plasticity and functional recovery after experimental stroke. Brain 2011;134:732-746.
8. Hedskog L, Pinho CM, Filadi R, et al. Modulation of the endoplasmic reticulum-mitochondria interface in Alzheimer's disease and related models. Proc Natl Acad Sci USA 2013;110:7916-7921.
9. Francardo V, Bez F, Wieloch T, et al. Pharmacological stimulation of Sigma-1 receptors has neurorestorative effects in experimental parkinsonism. Brain 2014;137:1998-2014.
10. Tomohisa M, Junpei O, Aki M, et al. Possible involvement of the Sigma-1 receptor chaperone in chemotherapeutic-induced neuropathic pain. Synapse 2015;69:526-532.
11. Yao H, Kim K, Duan M, et al. Cocaine hijacks Sigma1 receptor to initiate induction of activated leukocyte cell adhesion molecule: implication for increased monocyte adhesion and migration in the CNS. J Neurosci 2011;31:5942-5955.
12. Moriguchi S, Sakagami H, Yabuki Y, et al. Stimulation of Sigma-1 receptor ameliorates depressive-like behaviors in CaMKIV null mice. Mol Neurobiol 2015;52:1210-1222.
13. Hayashi T, Su TP. Sigma-1 receptor chaperones at the ER-mitochondrion interface regulate Ca(2+) signaling and cell survival. Cell 2007;131:596-610.
14. Su TP, Su TC, Nakamura Y, et al. The Sigma-1 receptor as a pluripotent modulator in living systems. Trends Pharmacol Sci 2016;37:262-278.
15. Hashimoto K. Sigma-1 receptor chaperone and brain-derived neurotrophic factor: emerging links between cardiovascular disease and depression. Prog Neurobiol 2013;100:15-29.
16. Urfer R, Moebius HJ, Skoloudik D, et al. Phase II trial of the Sigma-1 receptor agonist cutamesine (SA4503) for recovery enhancement after acute ischemic stroke. Stroke 2014;45:3304-3310.
17. Allahtavakoli M, Jarrott B. Sigma-1 receptor ligand PRE-084 reduced infarct volume, neurological deficits, pro-inflammatory cytokines and enhanced anti-inflammatory cytokines after embolic stroke in rats. Brain Res Bull 2011;85:219-224.
18. Ruscher K, Inacio AR, Valind K, et al. Effects of the sigma-1 receptor agonist 1-(3,4-dimethoxyphenethyl)-4-(3-phenylpropyl)-piperazine dihydro-chloride on inflammation after stroke. PLoS ONE 2012;7:e45118.
19. Chen F, Suzuki Y, Nagai N, et al. Rodent stroke induced by photochemical occlusion of proximal middle cerebral artery: evolution monitored with MR imaging and histopathology. Eur J Radiol 2007;63:68-75.
20. Paul R, Zhang ZG, Eliceiri BP, et al. Src deficiency or blockade of Src activity in mice provides cerebral protection following stroke. Nat Med 2001;7:222-227.
21. Cook DJ, Teves L, Tymianski M. Treatment of stroke with a PSD-95 inhibitor in the gyrencephalic primate brain. Nature 2012;483:213-217.
22. Kidwell CS. MRI biomarkers in acute ischemic stroke: a conceptual framework and historical analysis. Stroke 2013;44:570-578.
23. Chen YY, Wang X, Zhang JM, et al. Synthesis and evaluation of a 18F-labeled spirocyclic piperidine derivative as promising sigma1 receptor imaging agent. Bioorg Med Chem 2014;22:5270-5278.
24. Ye J, Wang X, Deuther-Conrad W, et al. Synthesis and evaluation of a (18) F-labeled 4-phenylpiperidine-4-carbonitrile radioligand for sigma1 receptor imaging. J Labelled Comp Radiopharm 2016;59:332-339.